

# Radioembolization with Yttrium-90 Glass Microspheres in Hepatocellular Carcinoma: European Experience on Safety and Long-Term Survival

Philip Hilgard,<sup>1</sup> Monia Hamami,<sup>2</sup> Amr El Fouly,<sup>1</sup> André Scherag,<sup>3</sup> Stefan Müller,<sup>2</sup> Judith Ertle,<sup>1</sup> Till Heusner,<sup>4</sup> Vito R. Cicinnati,<sup>1</sup> Andreas Paul,<sup>5</sup> Andreas Bockisch,<sup>2</sup> Guido Gerken,<sup>1</sup> and Gerald Antoch<sup>4</sup>

Radioembolization has been demonstrated to allow locoregional therapy of patients with hepatocellular carcinoma not eligible for transarterial chemoembolization or other local therapies. The aim of this study was to validate evidence of the safety and efficacy of this treatment in a European sample of patients with advanced hepatocellular carcinoma (HCC). Therefore, 108 consecutive patients with advanced HCC and liver cirrhosis were included. Yttrium-90 (Y-90) microspheres were administered in a lobar fashion over the right or left branch of the hepatic artery. The response to treatment was evaluated by computed tomography (CT) imaging applying Response Evaluation Criteria in Solid Tumors (RECIST) and World Health Organization (WHO) criteria with recent European Association for the Study of the Liver / National Cancer Institute (EASL/NCI) amendments. Time to progression (TTP) and overall survival were estimated by the Kaplan-Meier method. In all, 159 treatment sessions were performed ranging between one to three treatments per patient. The mean radiation dose per treatment was 120 ( $\pm 18$ ) Gy. According to EASL criteria, complete responses were determined in 3% of patients, partial responses in 37%, stable disease 53%, and primary progression in 6% of patients. TTP was 10.0 months, whereas the median overall survival was 16.4 months. No lung or visceral toxicity was observed. The most frequently observed adverse events was a transient fatigue-syndrome. **Conclusion:** Radioembolization with Y-90 glass microspheres for patients with advanced HCC is a safe and effective treatment which can be utilized even in patients with compromised liver function. Because TTP and survival appear to be comparable to systemic therapy in selected patients with advanced HCC, randomized controlled trials in combination with systemic therapy are warranted. (HEPATOLOGY 2010;52:1741-1749)

See Editorial on page 1528

Hepatocellular carcinoma (HCC) is a global health problem with increasing incidence worldwide. Today, therapy of HCC follows defined treatment algorithms and the most commonly used algorithm has been proposed by the Barcelona Liver Cancer Clinic (BCLC).<sup>1</sup> Standard therapy for patients with larger tumor sizes and no macrovascular invasion is transarterial chemoembolization (TACE).

TACE has been shown to prolong survival in patients with BCLC stage B (intermediate stage),<sup>2</sup> but has failed to show survival benefit in patients with advanced HCC, even in those patients with adequate hepatic functional reserve.<sup>3</sup> Therefore, in the current adaptation of the BCLC treatment algorithm the therapy of choice for advanced HCC is systemic treatment with sorafenib.<sup>4</sup> This multikinase inhibitor has recently been shown to prolong survival in patients with advanced HCC in a randomized, controlled phase III trial,<sup>5</sup> and is the first drug ever approved for the treatment of HCC.

Abbreviations: AE, adverse event; AFP, alphafetoprotein; BCLC, Barcelona Clinic Liver Cancer; HCC, hepatocellular carcinoma; MAA, macroaggregated albumin; PVT, portal vein thrombosis; RECIST, Response Evaluation Criteria in Solid Tumors; SIRT, selective internal radiotherapy; SPECT, single photon emission computed tomography; TACE, transarterial chemoembolization; Tc-99, technetium-99; TTP, time to progression; RILD, radiation-induced liver disease; Y-90, yttrium-90.

From the <sup>1</sup>Department for Gastroenterology and Hepatology, University Hospital Essen, Essen, Germany; <sup>2</sup>Department for Nuclear Medicine, University Hospital Essen, Essen, Germany; <sup>3</sup>Institute for Medical Informatics, Biometry and Epidemiology, University of Duisburg-Essen, Essen, Germany; <sup>4</sup>Department for Diagnostic and Interventional Radiology and Neuroradiology, University Hospital Essen, Essen, Germany; <sup>5</sup>Department for General, Visceral and Transplantation Surgery, University Hospital Essen, Essen, Germany.

Received May 13, 2010; accepted August 11, 2010.

Address reprint requests to (current address): Philip Hilgard, M.D., Associate Professor of Medicine, Department for Gastroenterology, Academic Teaching Hospital EVK, Wertgasse 30, 45468 Muelheim a.d.R., Germany. E-mail: philip.hilgard@evkmb.de; fax: +49-208-309-2628.

Due to the adverse effect profile of sorafenib, many patients can only tolerate a reduced dose or must discontinue the medication. This fact causes an ongoing effort to develop a locoregional treatment approach for patients with advanced HCC that is effective, but with a more acceptable/favorable toxicity profile than systemic therapy.

Microsphere-related transarterial application of radioactive agents into malignant tumors represents a new generation of therapeutics in interventional oncology, even though the first reports of this approach were published decades ago. The main reasons for the delayed acceptance of this method were the safety issues caused by pulmonary and gastrointestinal deposition of radioactive microspheres. Because these have recently been resolved,<sup>6</sup> different investigators reported the feasibility of this method not only in small and intermediate HCC, but also in advanced patients with or without vascular invasion who are not eligible for conventional local approaches, such as TACE.<sup>7</sup>

The main radioactive agent integrated with microspheres for radioembolization or selective internal radiotherapy (SIRT) is yttrium-90 (Y-90), although other agents have been reported. To date, two products for radioembolization with Y-90 microspheres are commercially available, based on resin or glass. Due to a smaller size and a significantly higher amount of radioactivity per single sphere,<sup>8</sup> glass microspheres do not show embolizing effects on larger tumor vessels. This limits exposure to surrounding liver tissue and allows glass microspheres to be utilized in the presence of portal vein thrombosis.<sup>7</sup>

We report the analysis of 108 consecutive cases with intrahepatic advanced HCC treated with Y-90 glass microsphere radioembolization. The aim of this study was to provide evidence on the safety of this therapy in this particular group of patients and to determine long-term survival, which has to be considered the most significant clinical endpoint.

## Patients and Methods

**Patient Sample, Staging, and Inclusion Criteria.** In all, 108 consecutive patients with advanced HCC who were treated with radioembolization with Y-90 glass microspheres at a single center (University Hospital Essen, Germany) between November 2006 and March 2009 were included in this observational cohort study. The indication for Y-90

treatment was driven by an institutional algorithm based on the BCLC treatment scheme. Patients were routinely staged by a 3-phase computed tomography (CT) or magnetic resonance imaging (MRI) of the liver, a contrast-enhanced ultrasound to further determine vascularity, as well as a CT of the lungs. If alpha-fetoprotein (AFP) was >400 ng/mL, patients additionally received a technetium-99 (Tc-99)-based bone scan.

The major clinical features allowing Y-90 treatment and therefore inclusion into this observational study were nonresectability of HCC and BCLC C tumor stage. Patients with BCLC A and B were also included if they were *not* eligible for selective TACE. Additional inclusion criteria were adequate hypervascularity (concentration and consecutive "blush" of contrast agent in the arterial phase of CT and/or contrast-enhanced ultrasound), a liver function with a Child-Turcotte-Pugh (CTP) score  $\leq 7$  points, and an Eastern Cooperative Oncology Group (ECOG) performance status of 0, 1, or 2.

Patients with proven extrahepatic manifestations of the disease were not treated with Y-90, but abdominal lymph nodes  $\leq 2$  cm and pulmonary nodules  $\leq 1$  cm were disregarded as extrahepatic metastasis and these patients received therapy. This approach was chosen because our institution is located in an area with a high incidence of lung granulomas (e.g., due to work in steel industry and coal mines). In addition, the approach allowed the treatment of patients with minimal (although at the point of inclusion unknown) extrahepatic disease who may have limited prognostic relevance.

**Y-90 Treatment.** Radioembolization with Y-90 glass microspheres (TheraSphere, MDS Nordion, Ottawa, Canada) was performed in a two-step process exactly as described in detail.<sup>6,8</sup> In addition, all patients received a whole body and a single photon emission (SPECT-) CT scan after injection of Tc-99 macroaggregated albumin (Tc99-MAA) into the hepatic artery for detection of radiation distributed to the lungs and/or visceral organs.

Following general recommendations,<sup>9</sup> an elevated hepatopulmonary shunt leading to exposure of the lungs of >30 Gy in a single session or >50 Gy in repeated sessions or the failure to prevent deposition of microspheres in extrahepatic abdominal locations were exclusion criteria for therapy with radioembolization. The major approach for the delivery of

microspheres was lobar infusion, although segmental application of microspheres had to be used occasionally to prevent visceral shunting. If a bilobar infusion of Y-90 microspheres was planned, this was performed sequentially and the time between both treatments was 3–4 weeks.

**Clinical Data, Follow-up, and Toxicities.** Clinical and biochemical data were measured at baseline (at least 2 weeks prior to therapy), during the first week after Y-90 treatment, and then 30, 60, and 90 days after Y-90 treatment followed by every 3 months, concomitant to the radiological follow-up.

Toxicity, response, and survival analyses were censored at the time of last clinic visit or death. All adverse events (AEs) were classified for severity using the NCI common toxicity criteria version 3 (CTCv3). All grade 3 or greater adverse events occurring within 30 days following any treatment with Y-90 microspheres was conservatively considered to be a possibly related AE.

**Evaluation of Radiological Response.** To assess tumor response and progression, the World Health Organization (WHO) tumor response criteria<sup>10</sup> and the Response Evaluation Criteria in Solid Tumors (RECIST)<sup>11</sup> were applied and complemented by the recent European Association for the Study of the Liver (EASL) and National Cancer Institute (NCI) amendments that define how to take tumor necrosis into consideration of response.<sup>12,13</sup> The reference point for all calculations of the radiological response and survival was the day of the first Y-90 treatment. The appearance of a new lesion as an indicator of progression was retrospectively adjudicated to the time it was first detected even if it were not considered at this point. The radiological response was examined at baseline, 30 days, 60 days, 90 days, and every 3 months thereafter, and in a single patient always with the same cross-sectional imaging method consisting either of triphasic spiral CT scan or MRI.

**Statistical Analyses.** Standard descriptive statistics were used to summarize the data (e.g., means and standard deviations [SD]). TTP and overall survival time in months was calculated as the difference between the date of the first treatment and the date of the event, or last observation date in case of censoring. Five patients received liver transplantation after treatment, and these cases were censored at the date of transplantation. Survival probabilities are displayed graphically by the Kaplan-Meier method; subgroup comparisons were performed by log-rank test. Survival probabilities at particular timepoints were reported as the closest observed event times.

All reported *P*-values are nominal, two-sided, and not adjusted for the testing of multiple hypotheses, i.e., we applied a significance level  $\alpha$  of 0.05 (two-sided) for each statistical test. In addition, we report 95% confidence intervals (95% CI) for estimated parameters. SAS v. 9.2 was used for statistical analyses.

## Results

**Patient Characteristics.** The demographics, tumor stages, and disease characteristics at baseline are shown in Table 1.

**Demographics and Liver Disease.** From the 108 patients finally treated with radioembolization, 80% were male. An additional nine patients were screened for therapy by angiography and following MAA-scan, but had to be excluded from therapy due to a high lung shunt fraction (2/117) or a noncorrectable gastrointestinal shunting of MAA particles (7/117). Most patients had evidence of liver cirrhosis, proved either by histology or by clinical (spider naevi, ascites), biochemical (impairment of liver function parameters), and imaging (splenomegaly, small liver with irregular surface) criteria. The mean age at time of therapy was  $64.9 \pm 11.8$  years. Grade 0 and 1 ECOG performance status was present in 51% and 44% of patients, respectively. Liver function was, as classified by Child Pugh score, in 76% of patients Child A and in 22% Child B.

**Tumor Staging.** In all, 62% of patients were therapy-naive; the rest received prior local therapy with curative or palliative intent. All patients were staged with different staging systems prior to therapy. In all, 51% of patients ( $n = 55$ ) were classified as BCLC stage C, whereas 47% ( $n = 51$ ) were BCLC stage B, but not eligible for selective TACE due to very large single lesions, multifocal bilobar disease, progression after previous TACE, or a complicated vascular anatomy.

Limited extrahepatic disease at baseline was possible in 30% of patients (small lung nodules in 17%, lymph nodes  $\leq 2$  cm in 16%). Portal vein thrombosis (PVT) as a sign of macrovascular invasion was diagnosed in 31% of patients (main branch 11%, lobar branch 9%, and segmental branch 2% when focusing on the primary lesion). Alpha-fetoprotein (AFP) was elevated beyond the upper normal level in 69% of patients, but this ratio decreased to 44% when the cutoff level was set  $\geq 200$  ng/dL and to 33% with a cutoff level of  $\geq 400$  ng/dL. Furthermore, 39% of patients had a tumor burden  $\geq 50\%$  of the target liver volume.

**Treatment Data.** The institutional therapeutic algorithm, which was based on the BCLC staging system,

**Table 1. Demographics and Baseline Characteristics of the Examined Patients (n = 108)**

Clinical Variables	Summary Statistics
Sex - n (%)	
Male	86 (80)
Female	22 (20)
Age at therapy - mean $\pm$ SD [years]	64.9 $\pm$ 11.8
Etiology of underlying liver disease - n (%)	
Hepatitis B	17 (16)
Hepatitis C	19 (18)
Alcoholic	18 (17)
Cryptogenic	19 (18)
Autoimmune	2 (2)
NASH	3 (3)
Toxic hepatitis	2 (2)
Noncirrhotic	28 (24)
ECOG Performance Status - n (%)	
0	55 (51)
1	48 (44)
2	5 (5)
BCLC stage - n (%)	
Stage A	2 (2)
Stage B	51 (47)
Stage C	55 (51)
Child-Pugh status - n (%)	
A	84 (77)
B	24 (22)
OKUDA stage - n (%)	
I	62 (57)
II	42 (39)
III	4 (4)
Clip score - n (%)	
0-2	77 (71)
3,4	28 (26)
5,6	3 (3)
Portal vein thrombosis - n (%)	33 (31)
Main branch	12 (11)
Right or left branch	10 (9)
Segmental branch	2 (2)
Details missing	9 (8)
Tumor burden - n (%)	
$\geq$ 50% of target volume	42 (39)
<50 % of target volume	66 (61)
Suspected extrahepatic spread - n (%)	32 (30)
Lung nodules	18 (17)
Lymph node metastases	17 (16)
Bone	6 (6)
Suprarenal gland	3 (3)
Others	3 (3)
Biochemistry	
Albumin - median (range) [g/dL]	3.9 (2.5-4.8)
Total bilirubin - median (range) [mg/dL]	0.9 (0.2-4.3)
Alpha-fetoprotein - median (range) [ng/mL]	100 (0-338,400)
$\geq$ 10 ng/mL - n (%)	72 (69)
$\geq$ 200 ng/mL - n (%)	44 (42)
$\geq$ 400 ng/mL - n (%)	35 (33)
Previous HCC therapy - n (%)	
Surgical resection	9 (8)
Loco-regional therapy	
TACE only	23 (21)
RFA only	1 (1)
TACE & RFA	8 (7)
Missing	5 (5)

Due to rounding, percentages may not always sum to 100%; for some characteristics multiple counts may have been present for each individual.

is shown in Fig. 1. The 108 patients received 159 sessions of radioembolization with Y-90 glass microspheres, mainly in lobar fashion. Sixty-one patients (56%) received one session, 43 patients (40%) received two sessions, and four patients (4%) received three sessions. Two patients had retreatment of the same target area after 9 and 12 months due to local progression. The mean first treatment dose was 120 ( $\pm$ 18) Gy and the corresponding mean lung shunt fraction was 7.96%. Prior to therapy, the occlusion of collaterals to the intestine vessels by application of platinum coils was done in 41% of cases.

**Radiological Response.** Patients who did not fit basic preconditions such as clearly definable margins of the tumor were excluded from the analysis of radiologic response, leaving a total of 76 patients with follow-up data 30 days after treatment initiation. To evaluate a potential bias of the results by this selection we analyzed group effects comparing the 32 to the 76 patients by explorative statistical tests. As expected, the 32 patients not assessable by radiology had on average a larger tumor burden and correspondingly slightly worse clinical stages; in all other factors like sex, age, or etiology we observed no evidence for differences between the groups.

Assessment was done according to four different evaluation guidelines: (1) RECIST; (2) RECIST with the recent NCI amendments (tumor necrosis and lack of enhancement/vascularity by  $-30\%$  = partial response)<sup>13</sup>; (3) WHO; and (4) WHO with EASL amendments (tumor necrosis and lack of enhancement/vascularity by  $-50\%$  = partial response).<sup>12</sup>

**Overall Response.** As shown in Table 2, the partial response, stable disease, and progressive disease rate for the entire sample using the conventional RECIST criteria after 3 months was 16%, 74%, and 10%, respectively. When RECIST criteria with NCI amendments were used for analysis, the response rate changed to 6% complete responders, 35% partial responders, 48% stable disease. Applying WHO criteria at the same point, partial response was detectable in 15%, stable disease in 79%, and progressive disease in 6% of patients. Incorporation of EASL modifications of WHO criteria lead to improvement of the rates to 3% complete responders, 37% partial responders, 53% stable disease. Progressive disease remained unchanged.

**Time to Progression.** Figure 2 shows the Kaplan-Meier plot for time to progression in 76 HCC patients treated with Y-90 glass microspheres for which radiological follow-up data were available. Although the median TTP for all patients was 10.0 months (95% CI 6.1-16.4 months), these numbers change to 8.0

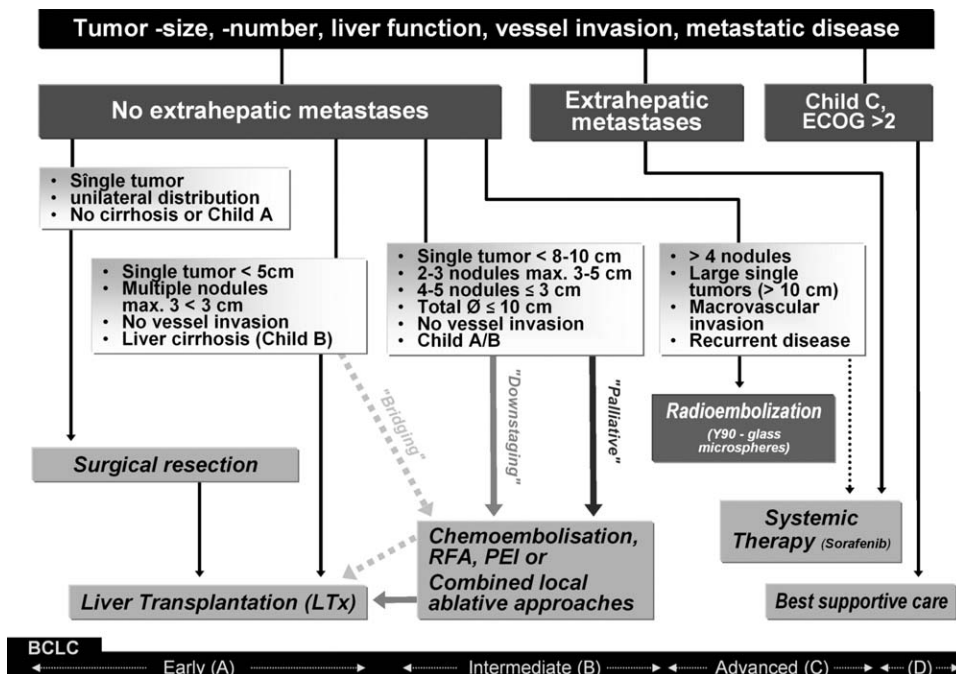


Fig. 1. Institutional treatment algorithm for patients with HCC at the University hospital in Essen, Germany, based on the BCLC staging system.

**Table 2. Assessment of Radiological Response in 76 of All 108 Patients After Radioembolization with Y-90 Microspheres According to Different Criteria/Guidelines at Different Follow-up Times**

Radiological Response	n (%)		
	30 Days After Treatment (n=76)	60 Days After Treatment (n=62)	90 Days After Treatment (n=62)
RECIST			
Complete or partial response	2 (3)	6 (10)	10 (16)
Stable disease	69 (90)	50 (80)	46 (74)
Progressive disease	5 (7)	6 (10)	6 (10)
RECIST including necrosis			
Complete response*	3 (4)	4 (6)	4 (6)
Partial response†	20 (26)	22 (35)	22 (35)
Stable disease	48 (63)	30 (48)	30 (48)
Progressive disease	5 (7)	6 (10)	6 (10)
WHO			
Complete or partial response	1 (1)	5 (8)	9 (15)
Stable disease	70 (92)	50 (80)	49 (79)
Progressive disease	5 (7)	7 (11)	4 (6)
WHO including necrosis			
Complete response‡	3 (4)	5 (8)	2 (3)
Partial response§	19 (25)	18 (29)	23 (37)
Stable disease	49 (64)	32 (52)	33 (53)
Progressive disease	5 (7)	7 (11)	4 (6)

Due to rounding, percentages may not always sum up to 100%.

\*Assessed as disappearance or total necrosis of the lesion compared to baseline.

†Assessed as either a relative size reduction  $\geq 30\%$  in comparison to baseline or a relative necrosis of  $\geq 30\%$  (devascularized areas in CT) according to RECIST criteria compared to baseline.

‡Assessed as disappearance or total necrosis of the lesion according to WHO criteria compared to baseline.

§Assessed as either a relative size reduction according to WHO by  $\geq 50\%$  in comparison to baseline or a relative necrosis of  $\geq 0\%$  according to WHO compared to baseline.

months (95% CI 5.9- $\infty$  months) for those with PVT and 11.8 months (95% CI 6.1-17.2 months) for those without evidence of PVT. The seldom event of a newly developing PVT with a stable tumor lesion at the same time was considered stable disease. Due to the small numbers within subgroups, no further prognostic factors were explored for TTP.

**Patient Survival.** Survival was determined from the day of first Y-90 treatment. Figure 3 shows the

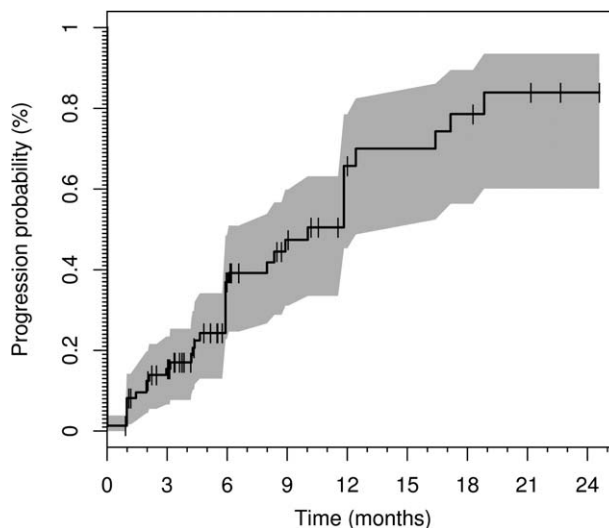


Fig. 2. TTP (with progression defined according to RECIST with the recent NCI amendments) in 76 of 108 HCC patients treated by Y-90 glass microsphere radioembolization for which radiological response data were available. The solid line displays the Kaplan-Meier estimator with marks representing censored events. The shaded area marks the limits of the pointwise 95% CIs.

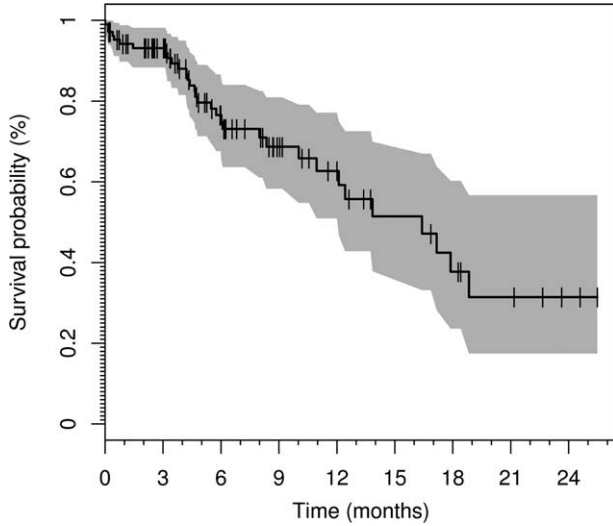


Fig. 3. Overall survival in 108 HCC patients treated by Y-90 glass microsphere radioembolization. The solid line displays the Kaplan-Meier estimator with marks representing censored events. The shaded area marks the limits of the pointwise 95% CIs.

Kaplan-Meier estimator with a median survival rate for the entire sample of 16.4 months (95% CI 12.1-inf. months). The corresponding survival probability at 6 months was 75% (95% CI 66%-85%), whereas it was 59% (95% CI 47%-75%) 1 year after treatment initiation. Significant differences were observed with respect to the survival times of patients with Child A liver cirrhosis as compared to patients with Child B (Fig. 4A,  $P = 0.013$ ). Although the estimated median survival rate in the Child A group was 17.2 months (95% CI 12.1-∞ months), the median survival rate in patients with Child B was only 6 months (95% CI 4.2-∞ months). Accordingly, the 6-month survival probability for Child A patients is 79% (95% CI 70%-90%) as compared to 16% (95% CI 23%-92%) for Child B patients.

Another important element that determines prognosis in patients with advanced HCC is the presence of macrovascular invasion. Figure 4B shows the difference in survival between patients with (31%) and without (69%) PVT. Survival probability in the PVT group at 6 months was 65% (95% CI 46%-92%) with a median survival rate of 10.0 months (95% CI 6.0-∞ months). In contrast, patients without detectable PVT had a survival probability of 76% (95% CI 65%-88%) and a median survival of 16.4 months (95% CI 12.1-∞ months).

When the tumor stage was used to stratify survival (Fig. 4C), we observed that patients with BCLC stage B had a median survival rate of 16.4 months (95% CI 12.1-∞ months). For patients with stage C no median

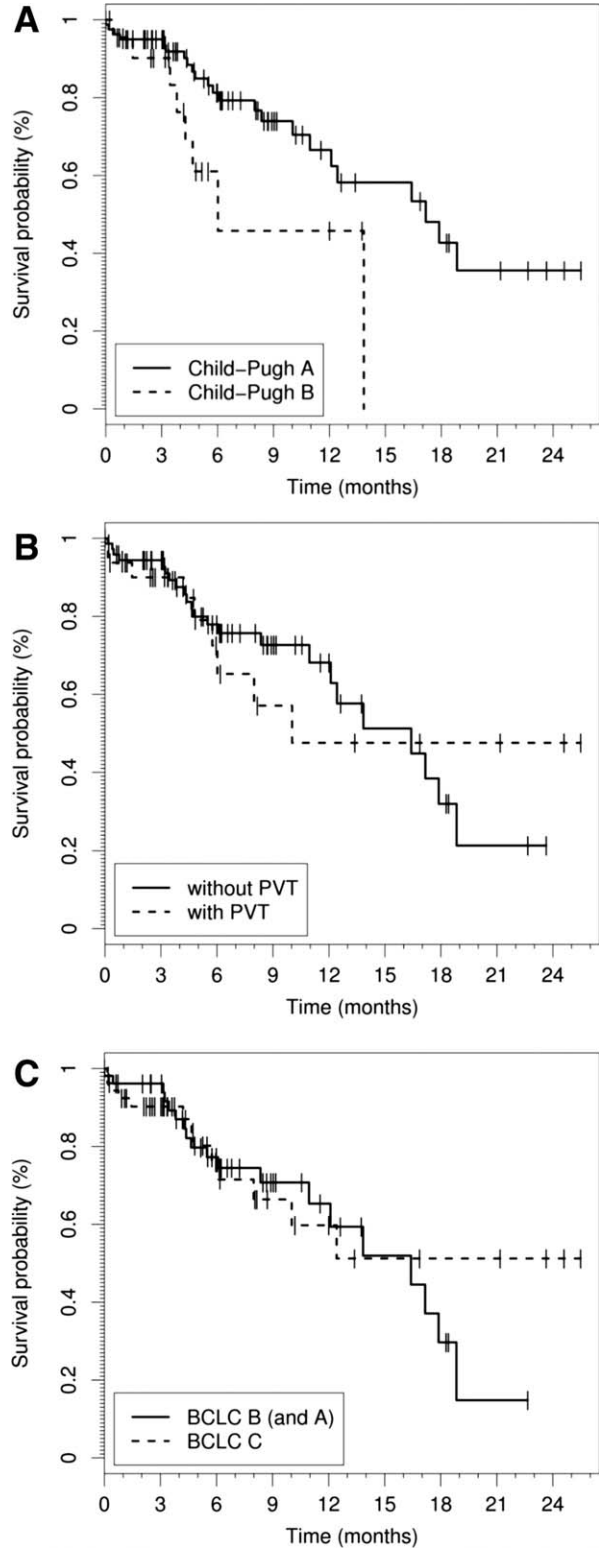


Fig. 4. Overall survival in 108 HCC patients treated by Y-90 glass microsphere radioembolization stratified by (A) liver function with respect to Child-Pugh score ( $P = 0.03$ ), (B) macrovascular invasion as determined by the presence of PVT ( $P = 0.96$ ), and (C) tumor stage according to the BCLC staging algorithm ( $P = 0.93$ ). The solid and dashed lines display the Kaplan-Meier estimators for the subgroups with marks representing censored events. For clarity, no information of patients at risk (i.e., confidence intervals) has been added to these figures.

survival rate was assessable, as the last estimate of survival probability in this group was 51% (95% CI 33%-81%). The corresponding survival probabilities at 6 months were 75% (95% CI 63%-89%) and 72% (95% CI 57%-87%), respectively.

**Clinical and Laboratory Toxicities.** The most commonly reported clinical AE was a transient fatigue syndrome with a maximum between day 3 and 7 post-therapy in 61% of patients and a vague abdominal pain reported by 56% of patients. A single case with radiation cholecystitis was the only relevant gastrointestinal AE; the patient was treated by cholecystectomy 10 days after Y-90 microsphere application. No patient experienced treatment-induced ulcerations in stomach or duodenum. In addition, we detected no patients with radiation-induced pneumonitis or other grade 3/4 AEs related to the lungs.

One patient showed dissection of the proper hepatic artery during treatment, resulting in a functional stenosis of the vessel. Due to preexisting collaterals by way of the gastroduodenal artery, this dissection remained without clinical consequences.

All bilirubin elevations that were observed within the observation period were considered treatment-related hepatotoxicity. In patients with normal values at baseline a grade 1/2 bilirubin elevation was detected in 32/108 patients (30%), whereas only three patients developed a grade 3 elevation (Table 3). In contrast, in patients who showed elevated bilirubin levels prior to therapy, 17% had grade 2 elevations and 30% had grade 3 or 4 elevations. It has to be noted that elevated bilirubin levels went back to baseline after 4-6 weeks in the majority of the affected patients (data not shown).

Three patients developed clinical signs of hepatic decompensation with grade 1/2 ascites and encephalopathy during the first month after therapy. One of these three patients also showed a spontaneous bacterial peritonitis, which was controlled by antibiotic therapy.

The only relevant hematologic alteration was lymphopenia. This event is well reported<sup>14</sup> and despite careful monitoring it has, in our patients, not been related to any clinical incidents.

## Discussion

Over the last decade, radioembolization has emerged as a viable treatment option for the locoregional management of primary and secondary liver tumors. One advantage of this treatment option is that Y-90 radioembolization can be performed in an unselective fash-

**Table 3. Clinical and Laboratory Toxicities After Y-90 Radiotherapy Graded According to NCI-CTCv3**

Clinical Toxicities		Grade 1/2 n (%)	Grade 3/4 n (%)
Fatigue syndrome		66 (61)	0 (0)
Abdominal pain		60 (56)	0 (0)
Ascites		3 (3)	0 (0)
Cholecystitis		0 (0)	0 (0)
Pneumonitis		0 (0)	0 (0)
GI ulcerations		0 (0)	0 (0)
Biochemical Toxicities	Presence at Baseline	Grade 1/2	Grade 3/4
		n (%)	n (%)
<i>Hematological parameters</i>			
WBC	-	23 (21)	0 (0)
	+	28 (26)	4 (4)
Hemoglobin	-	7 (6)	0 (0)
	+	16 (15)	0 (0)
Platelets	-	7 (6)	0 (0)
	+	16 (15)	4 (4)
Lymphopenia	-	0 (0)	12 (11)
	+	0 (0)	65 (60)
<i>Nonhematological parameters</i>			
INR	-	14 (13)	0 (0)
	+	20 (18)	3 (3)
Bilirubin	-	30 (27)	3 (3)
	+	18 (17)	22 (20)
GPT/ALT	-	21 (19)	0 (0)
	+	37 (34)	0 (0)
Alkaline phosphatase	-	7 (6)	0 (0)
	+	11 (10)	0 (0)
Albumin	-	10 (9)	0 (0)
	+	10 (9)	0 (0)
Creatinine	-	5 (5)	0 (0)
	+	7 (6)	0 (0)

ion. In contrast to TACE, the rate of AEs after such "unselective" application, as performed over the main or lobar branch of the hepatic artery, is not significantly increased as compared to segmental or even subsegmental microsphere application, although the tumor response rate may vary.<sup>15,16</sup>

Our study represents the first European report describing the use of Y-90 glass microspheres as a locoregional treatment in a relatively large number of patients with primary HCC. Interpreting the data of this study, certain limitations such as the study design (observational study of a patient cohort) and the data acquisition at a single center have to be considered. With respect to the evaluation of radiological response and TTP, not all patients were eligible for imaging analysis, mostly due to diffuse tumor growth.

**Safety.** With respect to overt clinical AEs, the most frequent symptoms reported were a transient fatigue syndrome and abdominal pain, which have been reported by other investigators to be the most common adverse reaction after therapy with Y-90 glass microspheres.<sup>7,17</sup>

Severe AEs that may be associated with radioembolization are radiation pneumonitis and gastrointestinal ulcerations. They are caused by the unintentional deposition of microspheres either through tumor-associated arteriovenous shunting into the lungs, or by way of collateral vessels to the intestine originating in the hepatic arterial system. Both of these AEs were not observed in our study due to careful selection and pretreatment diagnostic work-up. Pneumonitis is now generally considered a rare event in Y-90 microsphere treatment, as the introduction of the pretreatment Tc99-MAA scan, and the definition of maximal lung doses, as well as the fact that very likely higher cumulative doses than the recommended 50 Gy are well tolerated, has made it increasingly unlikely.<sup>9,18</sup>

In contrast, gastrointestinal ulcerations are occasionally reported, in particular with resin microspheres, where a 50-fold higher amount of spheres is necessary to deliver an equivalent amount of radioactivity into the tumor.<sup>8</sup> This increases the probability of blood stasis in the tumor supplying arterial vessel during therapy (=embolizing effect) causes enhanced probability of a backflow of spheres into small collateral arteries to the stomach, the duodenum, or the pancreas.<sup>19</sup> Although this phenomenon may be less frequent with Y-90 glass microspheres in general, we avoided it completely by introducing SPECT-CT after application of Tc99-MAA. The additional cross-sectional imaging of the MAA significantly enhanced the detection of accidental deposition of microspheres and has been reported by our group.<sup>20</sup> The value of SPECT-CT after MAA application in our study was in particular highlighted by nine patients who additionally underwent evaluation for Y-90 treatment, but ultimately were excluded (and therefore are not a part of this report) on the basis of increased pulmonary shunting or noncorrectable gastrointestinal shunting.

Because pneumonitis and gastrointestinal ulcerations were negligible, the third and probably most important safety issue in our study was hepatotoxicity by nontarget irradiation of liver tissue. The significance of hepatotoxicity is emphasized by the fact that HCC in Europe is present in >90% of patients with liver cirrhosis. In our cohort more than half of the patients showed a transient bilirubin elevation, corresponding to other reports of patients treated with radioembolization.<sup>17,21</sup> However, elevation of bilirubin, as a surrogate marker for hepatotoxicity, was only moderate and not related to clinically relevant symptoms in the majority of cases. The three patients who developed clinical signs of hepatic decompensation were all in Child B status with a CTP score >6 prior to initiation of

treatment, indicating that patients with detectable liver function impairment (Child B) are at increased risk for radiation-induced liver disease (RILD) and have to be selected very carefully. A future method to improve selection of patients in order to prevent RILD may be SPECT-CT, because it allows quantification of the uptake of spheres into the tumor as a function of its arterial hypervascularity as well as estimation of nontarget irradiation of the normal surrounding cirrhotic liver tissue.

**Radiological Response and Survival.** Radiological response parameters and in particular TTP are believed to predict survival after locoregional therapy. Moreover, both are important prognostic factors in an individual patient.<sup>13</sup> TTP in our sample was 10.0 months (95% CI 6.1-16.4 months) and corresponded well with the TTP reported in another large single-center study, where it was 7.9 months.<sup>17</sup> The measurable response rates in our study, however, were slightly lower as in the mentioned study, where an overall response rate of 42% was reported. A possible explanation for this phenomenon may be that our cohort consisted of more uniformly advanced tumors with either large, multifocal, or diffusely infiltrating tumors or PVT. Another difference may have been that we administered microspheres primarily by lobar injection, as opposed to the other study, where many applications were done in segmental or subsegmental fashion. Therefore, the radioactive dose within the tumor may have been too low to induce partial or complete devascularization, but high enough to effectively slow down tumor growth, resulting in increased TTP. Moreover, we followed a more conservative approach in the determination of necrosis and measured only those necrotic areas that were associated with the largest diameter of a particular tumor nodule.<sup>12,13</sup> Ill-defined or small areas of necrosis on the margins of a nodule, which were not uncommon, were not considered.

Therefore, in our study radioembolization behaves to some extent like systemic therapy with the multikinase inhibitor sorafenib, which also does not show significant radiological changes but a significantly enhanced TTP, translating in an enhanced overall survival.<sup>5</sup> In comparison with the phase III trial leading to approval of sorafenib (SHARP trial), the median overall survival in our HCC sample treated by Y-90 microsphere was even slightly longer (16.4 months as compared to 10.7 months). It is clear that due to a lower rate of patients with extrahepatic metastases and a number of other potential selection biases, our results are not comparable to those of this well-



designed double-blind, placebo-controlled trial. However, the overall survival rate as well as the substratified survival rates are similar to what have been reported in the only other recently published large sample analyzing Y-90 glass microspheres for the treatment of HCC.<sup>17</sup> Thus, our data indicate that Y-90 therapy requires further attention as a therapeutical option for the treatment of selected patients with advanced intrahepatic tumors, in particular with PVT and even in patients with limited extrahepatic disease.

**Conclusions and Perspectives.** The position of Y-90 microsphere treatment within the treatment algorithm of HCC is still to be defined. We report the results from an analysis of the first European sample of patients with intrahepatic advanced liver cancer treated with Y-90 glass microspheres. We demonstrate a very good toxicity profile, even in patients with advanced liver cirrhosis, as well as encouraging data for TTP and survival. As suggested by previous experiences in a U.S. study, our data further underline the role of Y-90 radioembolization as a locoregional therapy in patients with locally advanced tumor stages with or without PVT, and good liver function. Moreover, our data highlight the necessity for randomized controlled trials comparing and/or combining Y-90 glass microsphere radioembolization with TACE in BCLC B patients and with systemic therapy in BCLC C patients. However, such studies are difficult to perform, because survival differences may be low and with overall survival as the primary endpoint such studies may need a large number of included patients to provide evidence for an additional therapeutic effect. TTP as a primary endpoint in such studies seems to have some advantages but, as discussed above, the evaluation of response and progression shows particular difficulties in HCC after locoregional therapy. An additional necessity corroborated by our data are new dosimetry conceptions that incorporate the intrahepatic distribution of microspheres in the calculation of the applied dose aiming at lower exposure of normal liver tissue and, equally important, higher intratumoral radioactive doses. This may result in a further enhancement of local response, which should translate into a further improvement of overall survival.

## References

- Pons F, Varela M, Llovet JM. Staging systems in hepatocellular carcinoma. *HPB (Oxford)* 2005;7:35-41.
- Llovet JM, Real MI, Montana X, Planas R, Coll S, Aponte J, et al. Arterial embolisation or chemoembolisation versus symptomatic treatment in patients with unresectable hepatocellular carcinoma: a randomised controlled trial. *Lancet* 2002;359:1734-1739.
- A comparison of lipiodol chemoembolization and conservative treatment for unresectable hepatocellular carcinoma. Groupe d'Etude et de Traitement du Carcinome Hepatocellulaire. *N Engl J Med* 1995;332:1256-1261.
- Bruix J, Llovet JM. Major achievements in hepatocellular carcinoma. *Lancet* 2009;373:614-616.
- Llovet JM, Ricci S, Mazzaferro V, Hilgard P, Gane E, Blanc JF, et al. Sorafenib in advanced hepatocellular carcinoma. *N Engl J Med* 2008;359:378-390.
- Salem R, Thurston KG. Radioembolization with 90Yttrium microspheres: a state-of-the-art brachytherapy treatment for primary and secondary liver malignancies. Part 1: Technical and methodologic considerations. *J Vasc Interv Radiol* 2006;17:1251-1278.
- Kulik LM, Carr BI, Mulcahy MF, Lewandowski RJ, Atassi B, Ryu RK, et al. Safety and efficacy of 90Y radiotherapy for hepatocellular carcinoma with and without portal vein thrombosis. *HEPATOLOGY* 2008;47:71-81.
- Hilgard P, Muller S, Hamami M, Sauerwein WS, Haberkorn U, Gerken G, et al. Selective internal radiotherapy (radioembolization) and radiation therapy for HCC-current status and perspectives. *Z Gastroenterol* 2009;47:37-54.
- Kennedy A, Nag S, Salem R, Murthy R, McEwan AJ, Nutting C, et al. Recommendations for radioembolization of hepatic malignancies using yttrium-90 microsphere brachytherapy: a consensus panel report from the radioembolization brachytherapy oncology consortium. *Int J Radiat Oncol Biol Phys* 2007;68:13-23.
- Miller AB, Hoogstraten B, Staquet M, Winkler A. Reporting results of cancer treatment. *Cancer* 1981;47:207-214.
- Eisenhauer EA, Therasse P, Bogaerts J, Schwartz LH, Sargent D, Ford R, et al. New response evaluation criteria in solid tumours: revised RECIST guideline (version 1.1). *Eur J Cancer* 2009;45:228-247.
- Bruix J, Sherman M, Llovet JM, Beaugrand M, Lencioni R, Burroughs AK, et al. Clinical management of hepatocellular carcinoma. Conclusions of the Barcelona-2000 EASL conference. European Association for the Study of the Liver. *J Hepatol* 2001;35:421-430.
- Llovet JM, Di Bisceglie AM, Bruix J, Kramer BS, Lencioni R, Zhu AX, et al. Design and endpoints of clinical trials in hepatocellular carcinoma. *J Natl Cancer Inst* 2008;100:698-711.
- Salem R, Lewandowski RJ, Atassi B, Gordon SC, Gates VL, Barakat O, et al. Treatment of unresectable hepatocellular carcinoma with use of 90Y microspheres (TheraSphere): safety, tumor response, and survival. *J Vasc Interv Radiol* 2005;16:1627-1639.
- Kooby DA, Egnatashvili V, Srinivasan S, Chamsuddin A, Delman KA, Kauh J, et al. Comparison of yttrium-90 radioembolization and transcatheter arterial chemoembolization for the treatment of unresectable hepatocellular carcinoma. *J Vasc Interv Radiol* 2010;21:224-230.
- Lewandowski RJ, Kulik LM, Riaz A, Senthilnathan S, Mulcahy MF, Ryu RK, et al. A comparative analysis of transarterial downstaging for hepatocellular carcinoma: chemoembolization versus radioembolization. *Am J Transplant* 2009;9:1920-1928.
- Salem R, Lewandowski RJ, Mulcahy MF, Riaz A, Ryu RK, Ibrahim S, et al. Radioembolization for hepatocellular carcinoma using Yttrium-90 microspheres: a comprehensive report of long-term outcomes. *Gastroenterology* 2010;138:52-64.
- Salem R, Parikh P, Atassi B, Lewandowski RJ, Ryu RK, Sato KT, et al. Incidence of radiation pneumonitis after hepatic intra-arterial radiotherapy with yttrium-90 microspheres assuming uniform lung distribution. *Am J Clin Oncol* 2008;31:431-438.
- Carretero C, Munoz-Navas M, Betes M, Angos R, Subtil JC, Fernandez-Urien I, et al. Gastrointestinal injury after radioembolization of hepatic tumors. *Am J Gastroenterol* 2007;102:1216-1220.
- Hamami ME, Poepfel TD, Muller S, Heusner T, Bockisch A, Hilgard P, et al. SPECT/CT with 99mTc-MAA in radioembolization with 90Y microspheres in patients with hepatocellular cancer. *J Nucl Med* 2009;50:688-692.
- Kennedy AS, McNeillie P, Dezarn WA, Nutting C, Sangro B, Wertman D, et al. Treatment parameters and outcome in 680 treatments of internal radiation with resin 90Y-microspheres for unresectable hepatic tumors. *Int J Radiat Oncol Biol Phys* 2009;74:1494-1500.